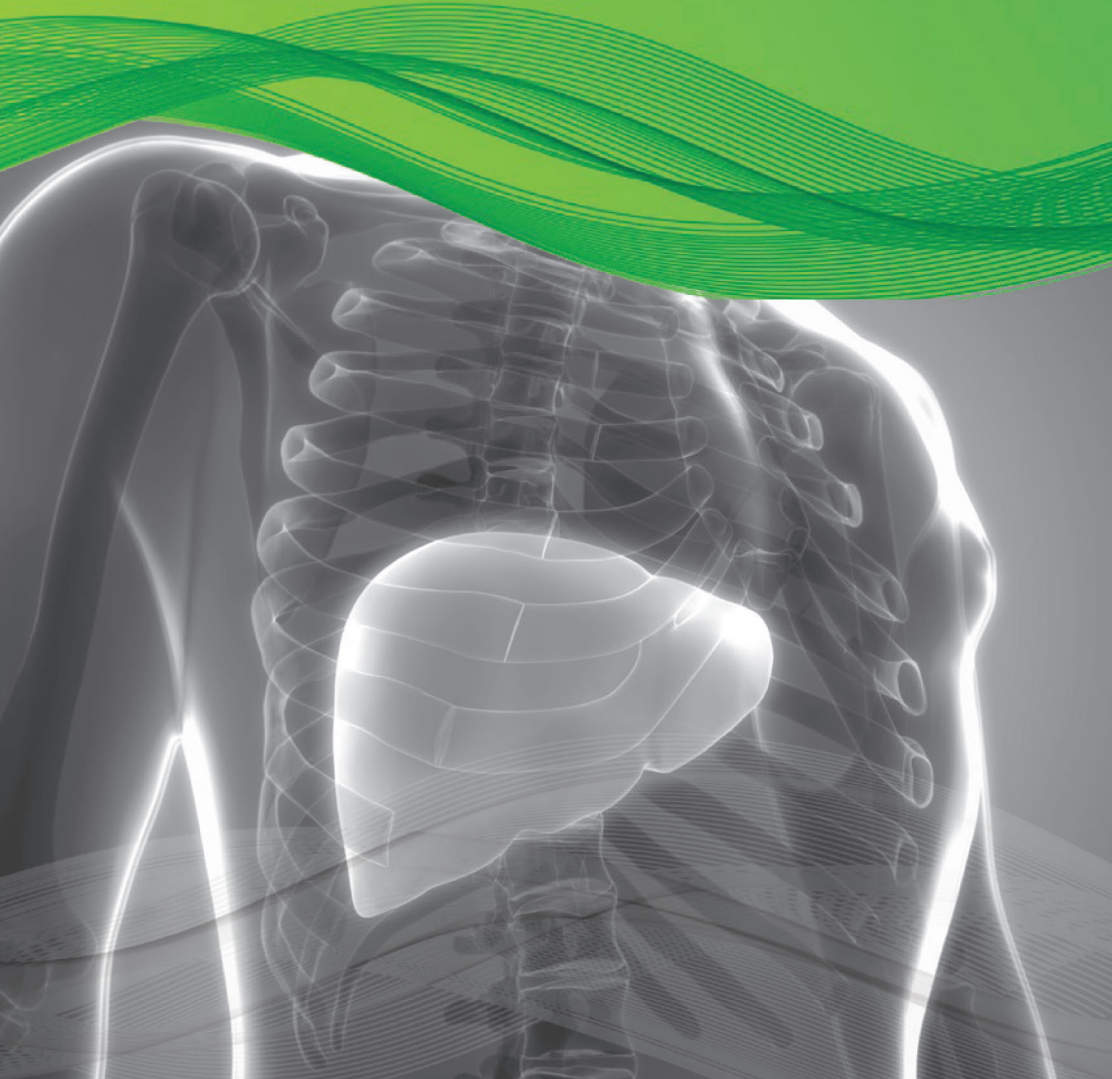

Verdye (Indocyanine Green)
Liver Focus



Diagnostic Green is the leading provider of trusted high quality fluorescence products, for physicians worldwide.

With primary liver cancer and colorectal liver metastases amongst the most common leading causes of cancer-related deaths worldwide, surgery represents one of the main treatments to obtain the best results in overall and disease free survival.¹ Verdye (Indocyanine Green, ICG) in recent years has experienced increased interest in use for its clearance parameters as a dynamic assessment of liver function both in medical and surgical settings.² ICG is used routinely to evaluate hepatic function and liver blood flow.³ It is one of the most common and easy-to-use tests for the perioperative dynamic assessment of liver function in cases of major liver surgery (resective surgery and liver transplantation) and in the intensive care unit.

USE OF VERDYE IN LIVER FUNCTION DIAGNOSTICS INCLUDE:

- ⊙ Measurement of excretory function of the liver
- ⊙ Measurement of liver blood flow

While numerous clinical parameters are used to assess a patient's liver function, the ICG test is the gold standard and is the only established test for estimating true global liver function.⁴ Assessment of dynamic liver function is crucial in the pre-operative preparation of those who require extensive liver resections, liver transplants and also to monitor liver function in a post-operative setting.

The ICG clearance or the elimination test is the most widely used quantitative liver function test. Following administration of ICG I.V., serial blood samples are collected at 5, 15, 20, 25 & 30 mins. The ICG blood levels fall exponentially for about 20mins, by which time approximately 97% of the ICG is excreted. After processing the samples, the ICG-R15 (at 15 mins) is determined as a percentage.

QUANTITATIVE MEASUREMENT

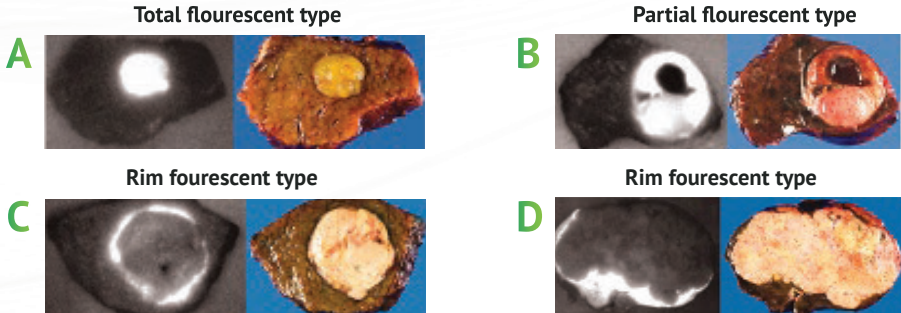
- ⊙ ICG Retention 15mins (ICG-R15) (Normal <10%)
- ⊙ Pulse Dye Densitometry – LiMON device
- ⊙ ICG Plasma Disappearance Rate (ICG-PDR) (Normal > 18%/min)⁵

ICG CLEARANCE TESTS

- ⊙ Pre and post Liver Resections
- ⊙ Pre and post Liver Transplant Surgery
- ⊙ Acute Liver Failure (ICU setting)

VERDYE AND TUMOUR VISUALISATION

For intra-operative visualisation of liver tumour, ICG is administered I.V. two weeks prior to surgery.¹⁰



- A** Total fluorescent type – well differentiated hepatocellular carcinoma (HCC), 7mm in diameter
- B** Partial fluorescent type – moderately differentiated HCC with well differentiated components and haemorrhagic necrosis at upper half of the tumour, 36mm in diameter
- C** Rim fluorescent type – poorly differentiated HCC, 30mm in diameter
- D** Rim fluorescent type – metastasis in colon carcinoma, 130mm in diameter

<p>Italy snapshot of LLR surgeries in practice ¹¹</p>	<p>GROWTH IN MINIMALLY INVASIVE LIVER SURGERIES BY YEAR IN ITALY (FROM 50 IN 2005 TO OVER 300 IN 2011)</p>
<ul style="list-style-type: none"> ⊙ LLR represents 10.3% of all Liver Resections (1677 cases) ⊙ Malignant lesions 72.5% (1085 cases) <ul style="list-style-type: none"> ⊙ 56% - Hepatocellular Carcinoma (HCC) ⊙ 28% - Colorectal Liver Metastases (CRLM) ⊙ Overall mortality 0.2% ⊙ Mean length of stay → five days 	

SUMMARY OF VERDYE (ICG) IN LIVER SETTING

- ⊙ Liver Function Assessment – Pre & Post Op
- ⊙ Intra-operative identification of anatomic liver segments
- ⊙ After reconstruction of hepatic vessels – assessment of liver inflow and outflow of blood
- ⊙ Visualisation of Liver Tumours (HCC & CRLM)
- ⊙ Useful for real-time detection of bile leaks during liver resection

LAPAROSCOPIC LIVER RESECTION (LLR)

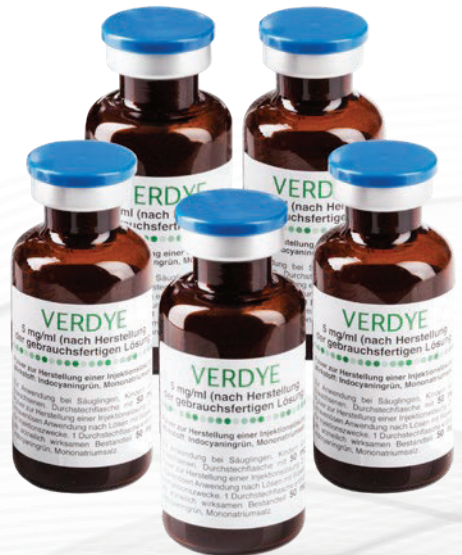Since the first Laparoscopic Liver Resection (LLR) was first preformed in 1991, the number of LLR's has increased with the advancements of surgical techniques and technology. LLR for Hepatocellular Carcinoma (HCC) is now considered standard treatment for minor liver resection.⁶ Laparoscopic surgery and robotic surgery have solved the issue of large incisional wounds, a major drawback of open liver surgery.⁷ While there are significant advantages associated with a laparoscopic technique (less bleeding, shorter length of hospital stay, decreased morbidity and possibly lower mortality), adoption by a surgeon does mean that the ability to touch and palpate the organ is eliminated. By using ICG in these circumstances, increasing the visualisation of the anatomy adds enormously to procedure success.

VERDYE USE IN LIVER RESECTIONS – FIRST LINE TREATMENT FOR HEPATOCELLULAR CARCINOMA (HCC)

Over the last few decades, imaging technologies in hepatobiliary (HPB) surgery have become indispensable tools for liver surgeons. The ICG fluorescence imaging (FI) technique helps to guide the hepatic surgical procedures and provides the surgeon with real-time visualisation of the fluorescent structures of interest that would be invisible under conventional white light. The extrahepatic bile duct anatomy and liver tumours can be emphasised, and hepatic segments highlighted, based on the fluorescence property of ICG and its biliary excretion.

COLORECTAL LIVER METASTASES AND LIVER TRANSPLANT USE OF ICG

Additionally, a recent retrospective multi-center analysis of 174 patients showed that the use of ICG identifies significantly more and smaller tumours during colorectal liver metastases (CRLM) resection.⁸ For liver transplantation, use of ICG has shown to be the best curative treatment of chronic liver diseases/HCC/acute liver failure. Increasing the use of marginal grafts can lead to increased incidence of primary non-function (PNF) after transplantation with few early predictors available for PNF. By undertaking quantitative assessment of intra-operative ICG fluorescence on the graft, a 2020 study has shown that it was feasible to predict graft survival at three months with good sensitivity and specificity.⁹



VERDYE USE - BENEFITS TO THE SURGEON

- Real time visualisation of anatomical structures
- Simple method to evaluate hepatic function
- Allows for safe use of marginal liver grafts
- Easy to use test for dynamic assessment of liver blood flow
- Helps identify more and smaller colorectal tumours
- Quantitative liver function test

REFERENCES:

- ¹Torre LA, Bray F, Siegel RL, Ferlay J, Lortet-Tieulent J, Jemal A. Global cancer statistics, 2012. *CA Cancer J Clin*. 2015;65:87–108. [PubMed] [Google Scholar]
- ²Indocyanine green kinetics to assess liver function: Ready for a clinical dynamic assessment in major liver surgery? Andrea De Gasperi, Ernestina Mazza, and Manlio Prosperi, *World J Hepatol*. 2016 Mar 8; 8(7): 355–367. Published online 2016 Mar 8. doi: 10.4254/wjh.v8.i7.355
- ³Fluorescence guided surgery in liver tumours: applications and advantages. Rossi Giorgio, Tarasconi Antonio, Baiocchi Gianluca, Luigi de'Angelis Gian, Gaiani Federica, Di Mario Francesco, Catena Fausto, and Dalla Valle Raffaele *Acta Biomed*. 2018; 89(Suppl 9): 135–140. doi: 10.23750/abm.v89i9-S.7974
- ⁴Geisel D, Lüdemann L, Hamm B, Denecke T. Imaging-Based Liver Function Tests--Past, Present and Future. *Rofo*. 2015;187(10):863-871. doi:10.1055/s-0035-1553306
- ⁵APA Sakka, Samir G. Assessing liver function, *Current Opinion in Critical Care: April 2007 - Volume 13 - Issue 2 - p 207-214*
- ⁶Kaneko J, Kokudo T, Inagaki Y, Hasegawa K. Innovative treatment for hepatocellular carcinoma (HCC). *Transl Gastroenterol Hepatol*. 2018;3:78. Published 2018 Oct 22. doi:10.21037/tgh.2018.10.04.
- ⁷The history of liver surgery: Achievements over the past 50 years. Norihiro Kokudo, Nobuyuki Takemura, Kyoji Ito, Fuminori Mihara. First published: 26 February 2020 <https://doi.org/10.1002/ags3.12322>
- ⁸Handgraaf HJM, Boogerd LSF, Höppener DJ, et al. Long-term follow-up after near-infrared fluorescence-guided resection of colorectal liver metastases: A retrospective multicenter analysis. *Eur J Surg Oncol*. 2017;43(8):1463-1471. doi:10.1016/j.ejso.2017.04.016
- ⁹Dousse D, Vibert E, Nicolas Q, et al. Indocyanine green fluorescence imaging to predict graft survival after orthotopic liver transplantation: a pilot study [published online ahead of print, 2020 May 13]. *Liver Transpl*. 2020;10.1002/lt.25796. doi:10.1002/lt.25796
- ¹⁰Ishizawa T, Fukushima N, Shibahara J, et al. Real-time identification of liver cancers by using indocyanine green fluorescent imaging. *Cancer*. 2009;115(11):2491-2504. doi:10.1002/ncr.24291
- ¹¹Aldrighetti L, Belli G, Boni L, et al. Italian experience in minimally invasive liver surgery: a national survey. *Updates Surg*. 2015;67(2):129-140

VERDYE PRESCRIBING INFORMATION

Name of the Medicinal Product

Verdye 5 mg/ml Injection

25 mg / 50 mg, Powder for Solution for Injection

Pharmaceutical Form

Powder for Solution for Injection
Dark-green powder

Clinical Particulars

Therapeutic indications

This medicinal product is for diagnostic use only.

Diagnostic Indications

Cardiac, circulatory and micro-circulatory diagnostics:

- measurement of cardiac output and stroke volume
- measurement of circulating blood volumes
- measurement of cerebral perfusion

Liver function diagnostics:

- measurement of liver blood flow
- measurement of excretory function of the liver

Ophthalmic angiography diagnostics:

- measurement of perfusion of the choroid

Posology and method of administration

Method of administration

Before administration the powder must be reconstituted with water for injection.

Shelf Life

5 years. After reconstitution, the solution should be used immediately, protected from light.

Instructions for use and handling

This medicinal product should be reconstituted immediately prior to use. This medicinal product is reconstituted by addition of 5 ml water for injections to the vial containing 25 mg of active substance or 10 ml water for injections to the vial containing 50 mg of active substance, respectively, giving in both cases a dark-green solution for injection with a concentration of 5 mg/ml (0.5 % w/v). If an incompatibility is noted in the form of unclear solution then the reconstituted solution should be discarded. Visually inspect the reconstituted solution. Only use clear solutions free from visible particles.

This medicinal product is for single use only.

The reconstituted solution is clear and free from visible particles.

Diagnostic procedures with Verdye should be performed under the supervision of a physician. Verdye is intended for intravenous injection via an injection needle, a central or peripheral catheter or cardiac catheter.

The administration and site of Verdye are of critical importance for the quality of the measurements. In principle, for obtaining optimal quality first pass indicator dilution curves, the injection should be as close as possible to the vascular bed, organ or tissue of interest.

On peripheral injection the injection should be made immediately after application of tourniquet and the arm should be raised after release of tourniquet. This ensures rapid transport of the dye from the site of injection and peripheral injection is then practically equivalent to central venous injection.

Dosage

Single dose per measurement in adults, elderly, children:

Cardiac, circulatory, micro-circulatory and tissue perfusion diagnostics as well as **cerebral blood flow**: 0.1 to 0.3 mg/kg body weight as bolus injection

Liver function diagnostics: 0.25 – 0.5 mg/kg body weight as bolus injection

Ophthalmic angiography: 0.1 to 0.3 mg/kg body weight as bolus injection

Total daily dose:

Adults, elderly, adolescents 11-18 years:

The total daily dose of Verdye should be kept below 5 mg/kg body weight.

Children 2 – 11 years:

The total daily dose should be kept below 2.5 mg/kg body weight.

Children 0 - 2 years:

The total daily dose should be kept below 1.25 mg/kg body weight.

Contraindications

Verdye is contraindicated for safety reasons in:

- patients with hypersensitivity to indocyanine green or to sodium iodide unless special precautions are taken,
- patients with hypersensitivity to iodine,
- patients with hyper-thyroidism, patients with autonomic thyroid adenomas
- as in-vitro experiments have shown that indocyanine green displaces bilirubin from its protein binding, Verdye should not be used in premature infants or neonates in whom an exchange transfusion is indicated due to of hyper-bilirubinemia,
- if injection of Verdye was poorly tolerated in the past it must not be used again, since severe anaphylactic reactions might occur.

For full prescribing information go to www.diagnosticgreen.com

Diagnostic
Green

© 2020 Diagnostic Green

info@diagnosticgreen.com
www.diagnosticgreen.com

Diagnostic Green GmbH
Otto-Hahn-Straße 20
85609 Aschheim-Dornach
Germany

Diagnostic Green LLC
38955 Hills Tech Drive
Farmington Hills
MI 48331, United States